

ANALYSIS OF RELATIONSHIPS BETWEEN HETEROGENEOUS RADIOMIC FEATURES OF THROMBUS IN ACUTE ISCHEMIC STROKE

Petra Nemcekova¹, Adam Skrvan², Henk Marquering³, Jiri Chmelik¹, Roman Jakubicek¹

¹Brno University of Technology, Brno, Czech Republic

²Univerzity of Žilina, Žilina, Slovakia

³Amsterdam University Medical Centers, Amsterdam, Netherlands

Abstract

Ischemic stroke is one of the most widely recognised cerebral pathologies. Its diagnosis starts with computed tomography (CT). However, a comprehensive understanding of the characteristics of the thrombus is necessary to establish an appropriate and less hazardous treatment. This study focusses on the analysis of thrombus heterogeneity in CT images of patients with acute ischemic stroke (AIS). The radiomic features of the thrombus were used to obtain the voxel distribution in the new feature space. It was then reduced using Principal Component Analysis (PCA) and subjected to visualisation techniques such as t-distributed Stochastic Neighbour Embedding (tSNE) and Uniform Manifold Approximation and Projection for Dimension Reduction (UMAP). By evaluating the morphological structure of the clusters created within patients, it was possible to determine the number of thrombus components. This information could help the physician predict the burden on the patient during thrombectomy, such as the number of attempts required for recanalization.

Keywords

ischemic stroke, thrombus, radiomics, heterogeneity, computed tomography

Introduction

Cerebrovascular accidents are categorized into ischemic and haemorrhagic types. Ischemic cerebral infarction (ICI) represents a pathological condition induced by disruption of the blood supply to a specific region of the brain due to the occlusion of the vessel responsible for the delivery of blood to that area. The primary diagnostic method when suspecting a cerebrovascular cerebral infarction is computed tomography (CT). On a non-contrast CT (nCT) scan, the thrombus may appear as a hyperdense artery sign (HAS). In contrast-enhanced CT angiography (CTA), the thrombus can be identified as an interruption in the contrast-enhanced vessel. Following the confirmation of ICI, it becomes essential to select an appropriate therapeutic approach, including endovascular mechanical thrombectomy and intravenous thrombolysis.

However, to our knowledge, no standardised approach has been established for therapy selection.

One of the key factors to achieve a better prognosis for the patient is time and accurate determination of therapy. Currently, treatment involves the administration of thrombolytic drugs immediately after the exclusion of haemorrhagic stroke. In the cases where this treatment is found to be ineffective, an endovascular mechanical thrombectomy is followed. However, the time that elapses while waiting for the assessment of thrombolysis effectiveness can have a crucial impact on the patient's future quality of life. Therefore, recent research has focused on methods that allow for earlier determination of the appropriate therapy for the patient based on CT images.

Radiomics [1] is a method that extracts a large number of features from radiological image data that are not observable by the human eye. These features are acquired through a wide spectrum of methods, such

as first-order and second-order statistical operators, Gaussian and Laplacian filtration, or wavelet transformation [2]. Radiomic analysis is most commonly used in the study of oncological diseases [3]. However, recent research has also begun to focus on radiomics in patients with ischemic stroke. In the article [4], the authors have successfully identified a strong correlation between five radiomic features, obtained using wavelet transformation and haemorrhagic transformation in patients with ICI. The authors of [5] have unveiled specific relationships between thrombus texture, its volume, reperfusion, and the number of attempts required for successful reperfusion.

Many of the radiomic features are associated with thrombus heterogeneity. In the article [1], the authors identified a relationship between the heterogeneity features of the thrombus obtained using a combination of CTA and nCT and early reperfusion using intravenous alteplase. The authors of [6] highlighted the association between 12 heterogeneity features and the First Pass Effect (FPE), with these features, according to their findings, being independent predictors of FPE.

However, to the best of our knowledge, the thrombus morphology with the use of radiomic features of heterogeneity at the level of individual voxels obtained from nCT data have not been investigated so far. The discovery of connections between thrombus heterogeneity and voxel distribution in the feature space could contribute to a deeper understanding of acquired CT data and subsequently facilitate the selection of the appropriate therapy for each patient. Therefore, our study is focused on analysis of local thrombus heterogeneity by extracting local radiomic features for individual thrombus voxels and conducting their cluster analysis using both hierarchical and non-hierarchical methods.

Materials and Methods

Data were acquired using a Brilliance iCT 256 scanner (Phillips Medical Systems, Eindhoven, Netherlands) following the standard clinical protocol for acute ischemic events, which did not require approval from an ethical committee. The data included native non-contrast CT (nCT), covering the region from the skull base to the vertex. All slices had a thickness of 0.9 mm with axial overlap. Informed consent was obtained from all participants, and all procedures conducted in human studies adhered to ethical standards set by institutional and/or national research committees and were in compliance with the

Helsinki Declaration of 1964 and its subsequent amendments.

This contribution aims to uncover relationships among patient's thrombi and their local areas based on extracted features. Initially, a representative (binary) segmentation mask of the thrombus was created. This process involved independent segmentation masks provided by six annotators, including radiologists with extensive experience, practising radiologists, and a trained biomedical engineer. The final mask was generated by majority agreement among the annotators. If a minimum of three annotators agreed that a particular voxel was part of the thrombus, that voxel was labelled as its part in the resulting representative mask.

Based on this mask, local radiomic features were extracted for each thrombus voxel using the PyRadiomics package [7]. Only features related to thrombus heterogeneity, such as variance, entropy, or the range of values in the voxel's neighbourhood, were utilised. Voxels for which some features could not be computed were subsequently removed. Subsequently, the features were dimensionally reduced using Principal Component Analysis (PCA). The principal components (PCs) were then included in further visualization analysis using the Uniform Manifold Approximation and Projection for Dimension Reduction (UMAP) method and the t-distributed Stochastic Neighbour Embedding (tSNE) method. For the UMAP method, the number of output components was set to 2, the minimum distance was set to 0.1, and the Euclidean distance metric was used. For the tSNE method, the perplexity value was empirically set to 40, which provided the successful separation of clusters.

Manual thrombus segmentation was performed using the Medical Imaging Interaction Toolkit (MITK) software [8], version v2022.10. The entire analyses, from obtaining the representative thrombus mask to cluster analysis, was implemented in Python 3.7.9, utilising the PyRadiomics package version 3.0.1a1 [7], umap-learn 0.5.3 [9], and sklearn 1.0.2 [10] libraries.

Results

For each voxel lying under thrombus mask, 1205 image features were extracted. Due to the high dimensionality of this feature space, which is often characterised by a significant degree of inter-dependence among the features, dimensionality reduction was performed using PCA. The distribution of voxels from nCT scans of all patients based on the first two principal components obtained by PCA is depicted in Fig. 1.

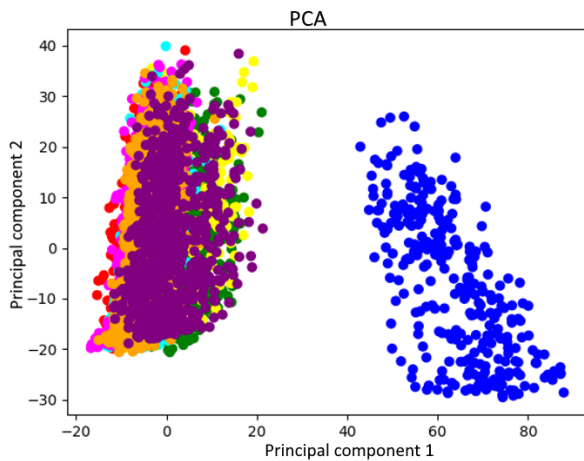


Fig. 1: Visualisation of the distribution of patient voxels (colour-coded) based on PCs obtained through PCA using the eight patients as input. The variance of PC1 was explained by the patient represented by a blue colour.

Due to the high variance explained by the features in the blue-labelled patient, who exhibits a prominent Hyperdense Artery Sign (HAS) distinct from the others, was excluded from further analysis. Following the removal of this patient, PCA was applied again, and the results are illustrated in Fig. 2.

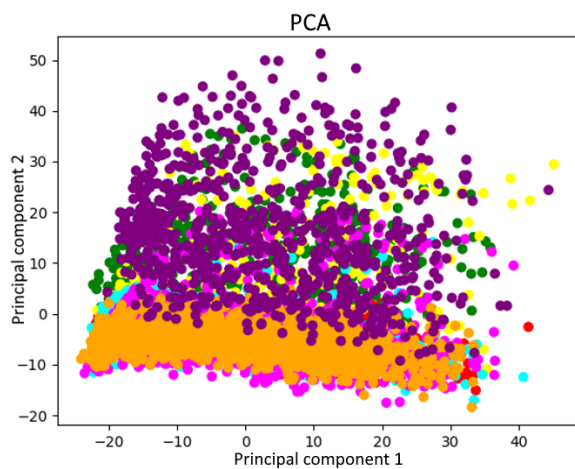


Fig. 2: Visualisation of the distribution of patient voxels (colour coded) based on PCs obtained through PCA after the exclusion of the patient labelled blue due to their significant variance, which had a substantial impact on the overall variability.

After applying PCA, no distinct clusters were observed. Therefore, 86 principal components, covering 90% of the total feature variability, were selected as inputs for the tSNE and UMAP methods. The resulting distribution of voxels from individual

patients based on the components obtained through these methods can be seen in Fig. 3 and Fig. 4.

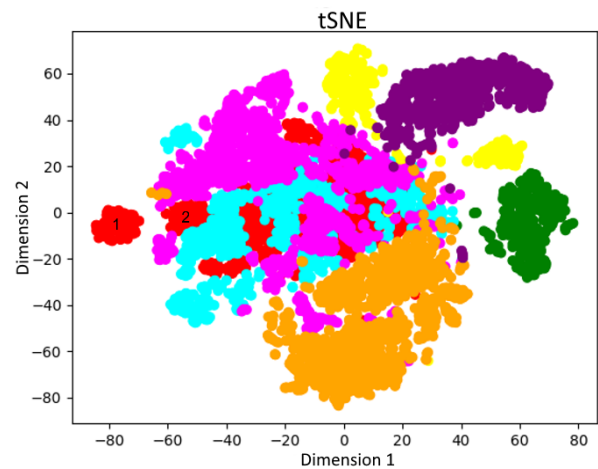


Fig. 3: Visualisation of the results after applying the tSNE method to PCs obtained through the PCA. Different colours represent voxels from individual patients. Numbers 1 and 2 in the graphs indicate the positions from which the voxels were selected for further analysis.

For some patients, such as the one labelled in green and purple, a concentration of all thrombus voxels into a single cluster is evident when using both methods. Since these features describe heterogeneity, it can be assumed that the thrombi in these patients exhibit a high degree of homogeneity and are not composed of significantly different parts. Conversely, for the patient labelled in yellow, it is apparent that two separate clusters are formed using the tSNE, whereas in the visualisation of the new feature space obtained using the UMAP method, all voxels within this patient's thrombus are in a single cluster. A more detailed analysis focussing on the voxels within the individual sub-clusters in the tSNE method could potentially reveal whether this represents a significant separation within the thrombus.

Another intriguing aspect that can be observed in the results obtained in Fig. 3 and Fig. 4 is the division of the thrombus in the patient labelled in red into at least two clusters in both methods. In the tSNE method, there is a small cluster on the left side of the graph and a larger cluster on the right. In Fig. 3 and Fig. 4, it might initially appear that this cluster is composed of several smaller clusters. Similarly, in the graph that displays the results using the UMAP method, a smaller, isolated cluster of the red-labelled patient's thrombus is located at the top of the graph, while the second large cluster, or possibly other smaller clusters, is located below it.

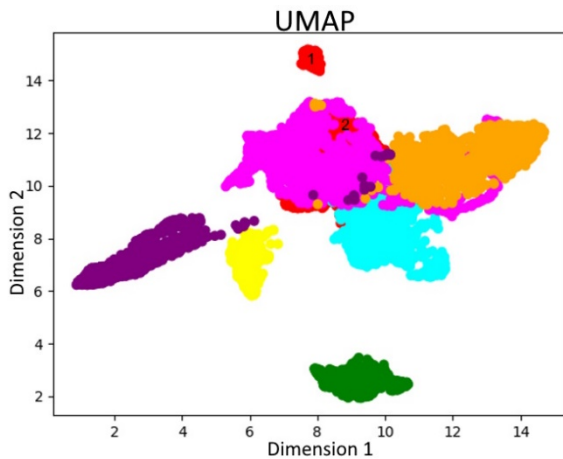


Fig. 4: Visualisation of the results after applying the UMAP method. to PCs obtained through the PCA. Different colours represent voxels from individual patients. Numbers 1 and 2 in the graphs indicate the positions from which the voxels were selected for further analysis.

For a closer analysis of the clusters, central voxels from two clusters were selected. The positions of these two voxels for further analysis can be seen in Fig. 3 and Fig. 4, marked with the numbers 1 and 2 in both graphs. However, these represent the same voxels in the original space. In Fig. 5, you can observe the positions of these two voxels on the thrombus heterogeneity map. It is evident that these two clusters represent different parts of the thrombus, with the cluster marked by the red point on the heterogeneity map and also labelled as number 2 in the resulting graphs using the UMAP and tSNE methods representing an area of the thrombus with high heterogeneity. Conversely, the area of the thrombus represented by cluster number 1 and the green point on the heterogeneity map indicates a more homogeneous region.

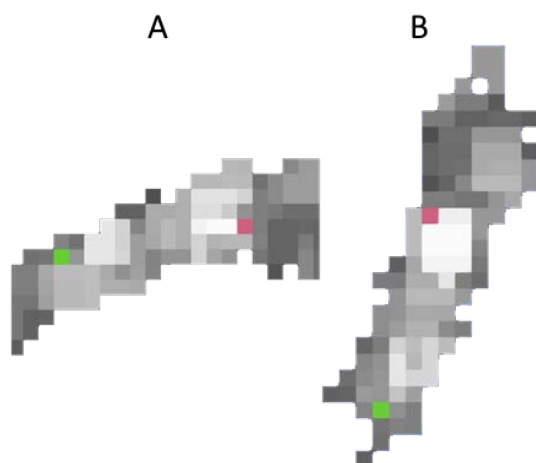


Fig. 5: Heterogeneity map with highlighted positions of central points from clusters. The green point represents voxel 1, and the red point represents voxel 2 in axial plane (A) and coronal plane (B).

Discussion

Analysis has revealed that the number of clusters obtained through the features of heterogeneity and subsequent analysis may directly correlate with the number of thrombus regions with different compositions. This is likely related to the number of attempts required for successful recanalization in clinical practice, the chemical composition of the thrombus, or its mechanical properties.

This study has several limitations. The first is the small size of the dataset, which consisted of only eight patients. The second limitation is the feature extraction using a representative mask. When utilising features extracted separately for each annotator, it would likely be possible to discover features that are sensitive to labelling noise, which could provide deeper insights into the relationships among the features.

Conclusion

The study focused on the analysis of thrombus heterogeneity in CT images of patients with ischemic cerebrovascular stroke. Using radiomic analysis and Principal Component Analysis (PCA), reduced features related to thrombus heterogeneity were obtained. The results showed varying distributions of voxels in the feature space, with multiple clusters forming in some patients. In contrast, in other patients, only one cluster was formed, attributed to the uniformity of the thrombus. In cases where the thrombus was divided into multiple clusters, their different character was subsequently confirmed.

Therefore, future studies should emphasise the significance and clinical impact of thrombus areas divided into clusters, which could assist in predicting the number of attempts required for successful recanalization, as well as provide insights into the mechanical properties and chemical composition of the thrombus. This, in turn, could facilitate a medical physician's decision in selecting appropriate treatment options.

Acknowledgement

This research would not have been possible without the support of Philips Healthcare. The authors also extend their gratitude to MSc. Tomáš Holeček from the Faculty Hospital at St. Anne in Brno for the preparation and provision of valuable patient data. They also thank Dr. Petr Ouředníček, MD and Associate Professor Jiří Vaníček, MD for their contribution to the research project.

References

- [1] Qiu W, Kuang H, Nair J, Assis Z, Najm M, McDougall C, et al. Radiomics-Based Intracranial Thrombus Features on CT and CTA Predict Recanalization with Intravenous Alteplase in Patients with Acute Ischemic Stroke. *American Journal of Neuroradiology*. 2019 Jan;40(1):39–44. DOI: [10.3174/ajnr.A5918](https://doi.org/10.3174/ajnr.A5918)
- [2] Lubner MG, Smith AD, Sandrasegaran K, Sahani DV, Pickhardt PJ. CT Texture Analysis: Definitions, Applications, Biologic Correlates, and Challenges. *Radiographics*. 2017 Sep 12;37(5):1483–503. DOI: [10.1148/rg.2017170056](https://doi.org/10.1148/rg.2017170056)
- [3] Shur JD, Doran SJ, Kumar S, ap Dafydd D, Downey K, O'Connor JP, et al. Radiomics in Oncology: A Practical Guide. *Radiographics*. 2021 Oct 1;41(6):1717–32. DOI: [10.1148/rg.2021210037](https://doi.org/10.1148/rg.2021210037)
- [4] Xie G, Li T, Ren Y, Wang D, Tang W, Li J, et al. Radiomics-based infarct features on CT predict hemorrhagic transformation in patients with acute ischemic stroke. *Frontiers in Neuroscience*. 2022 Sep 21;16:1002717. DOI: [10.3389/fnins.2022.1002717](https://doi.org/10.3389/fnins.2022.1002717)
- [5] van Voorst H, Bruggeman AA, Yang W, Andriessen J, Welberg E, Dutra BG, et al. Thrombus radiomics in patients with anterior circulation acute ischemic stroke undergoing endovascular treatment. *Journal of NeuroInterventional Surgery*. 2023 Aug 29;15(e1):e79–85 DOI: [10.1136/jnis-2022-019085](https://doi.org/10.1136/jnis-2022-019085)
- [6] Sarioglu O, Sarioglu FC, Capar AE, Sokmez DF, Mete BD, Belet U. Clot-based radiomics features predict first pass effect in acute ischemic stroke. *Interventional Neuroradiology*. 2021 May 18;28(2):160–8. DOI: [10.1177/15910199211019176](https://doi.org/10.1177/15910199211019176)
- [7] van Griethuysen JJ, Fedorov A, Parmar C, Hosny A, Aucoin N, Narayan V, et al. Computational Radiomics System to Decode the Radiographic Phenotype. *Cancer Research*. 2017 Nov 1; 77(21):e104–7. DOI: [10.1158/0008-5472.CAN-17-0339](https://doi.org/10.1158/0008-5472.CAN-17-0339)
- [8] Wolf I, Vetter M, Wegner I, Böttger T, Nolden M, Schöbinger M, et al. The Medical Imaging Interaction Toolkit. *Medical Image Analysis*. 2005 Dec;9(6):594–604. DOI: [10.1016/j.media.2005.04.005](https://doi.org/10.1016/j.media.2005.04.005)
- [9] McInnes L, Healy J, Saul N, Großberger L. UMAP: Uniform Manifold Approximation and Projection. *Journal of Open Source Software*. 2018 Sep 2;3(29):861. DOI: [10.21105/joss.00861](https://doi.org/10.21105/joss.00861)
- [10] Pedregosa F, Varoquaux G, Gramfort A, Michel V, Thirion B, Grisel O, et al. Scikit-learn: Machine Learning in Python. *Journal of Machine Learning Research*. 2011 Nov 1;12:2825–30.

Petra Nemčėková

*Department of Biomedical Engineering Faculty of
Electrical Engineering and Communication
Brno University of Technology
Technická 3058/10, CZ-616 00 Brno*

E-mail: xnemce05@vutbr.cz

Phone: +421 949 716 769